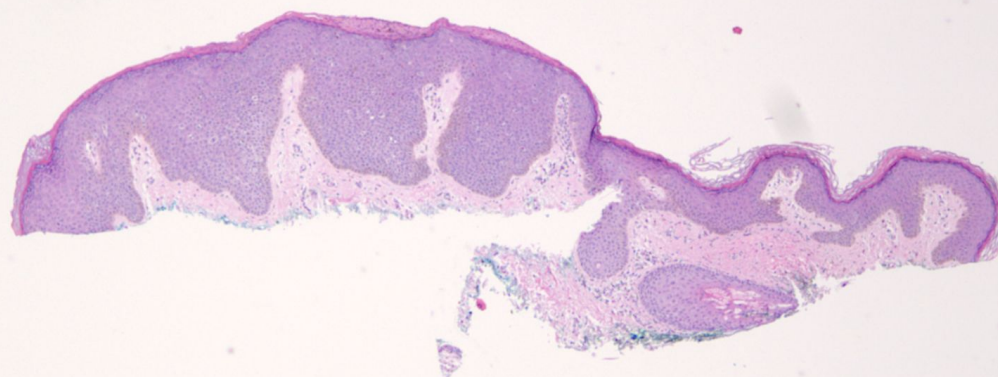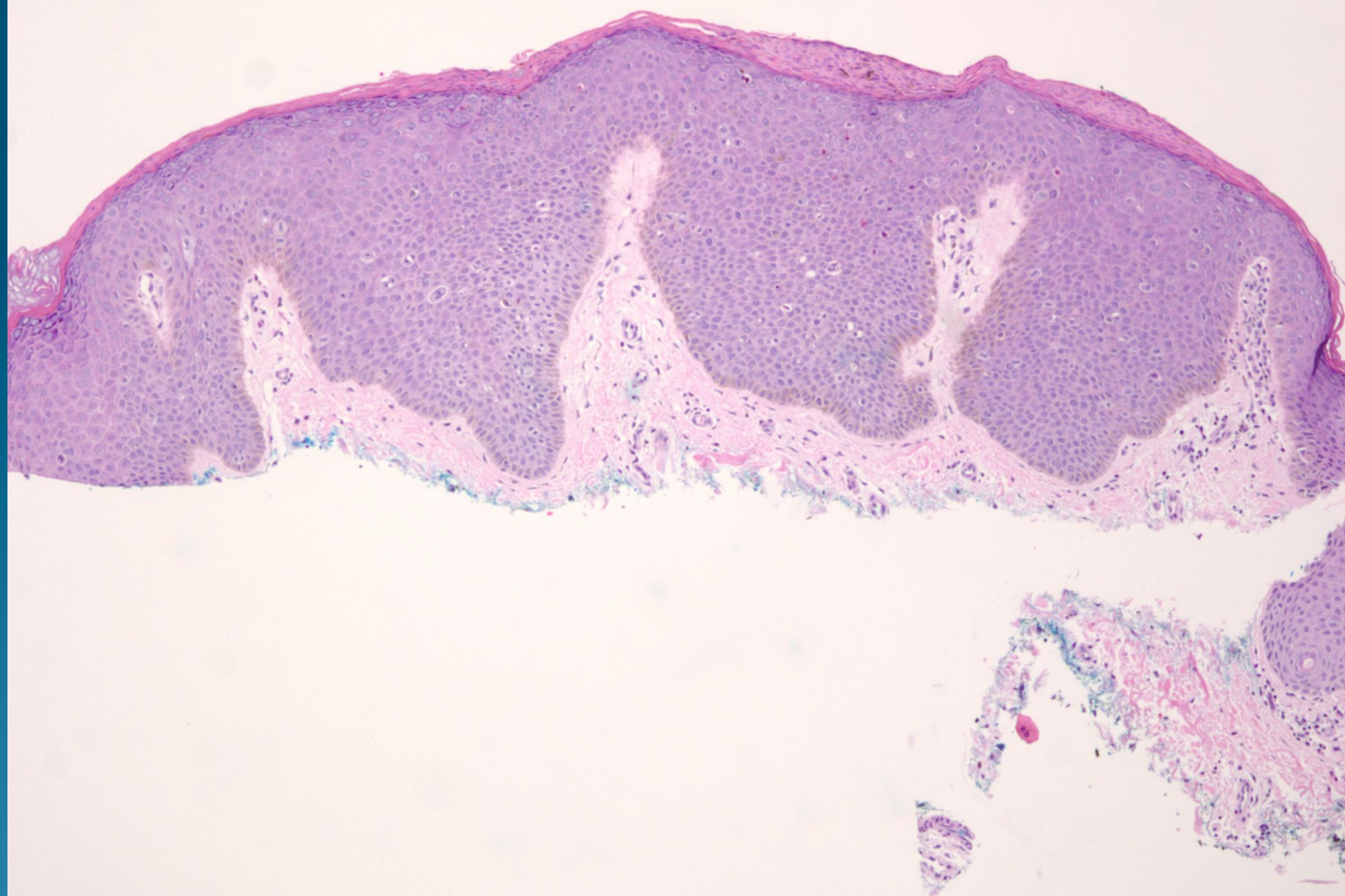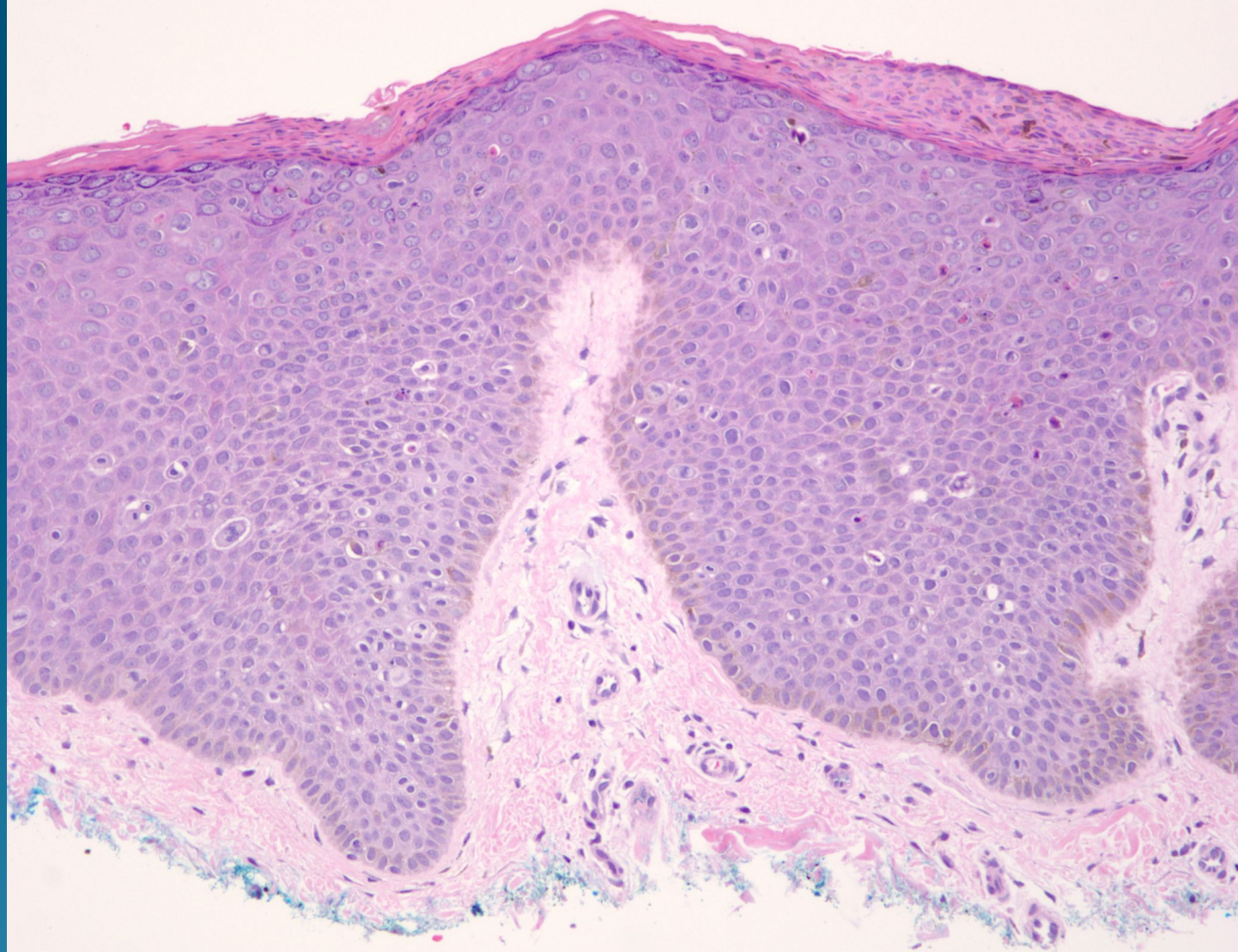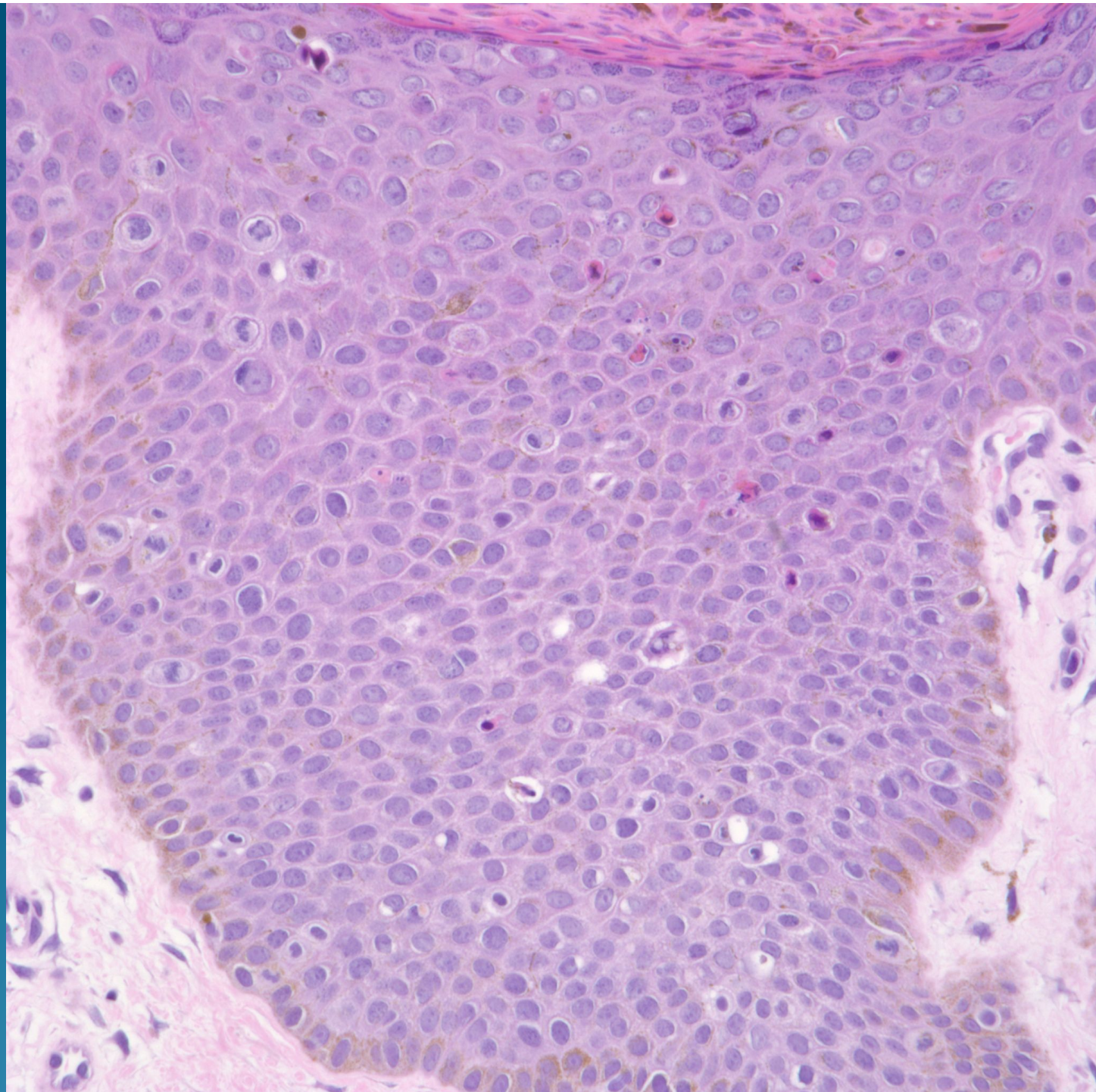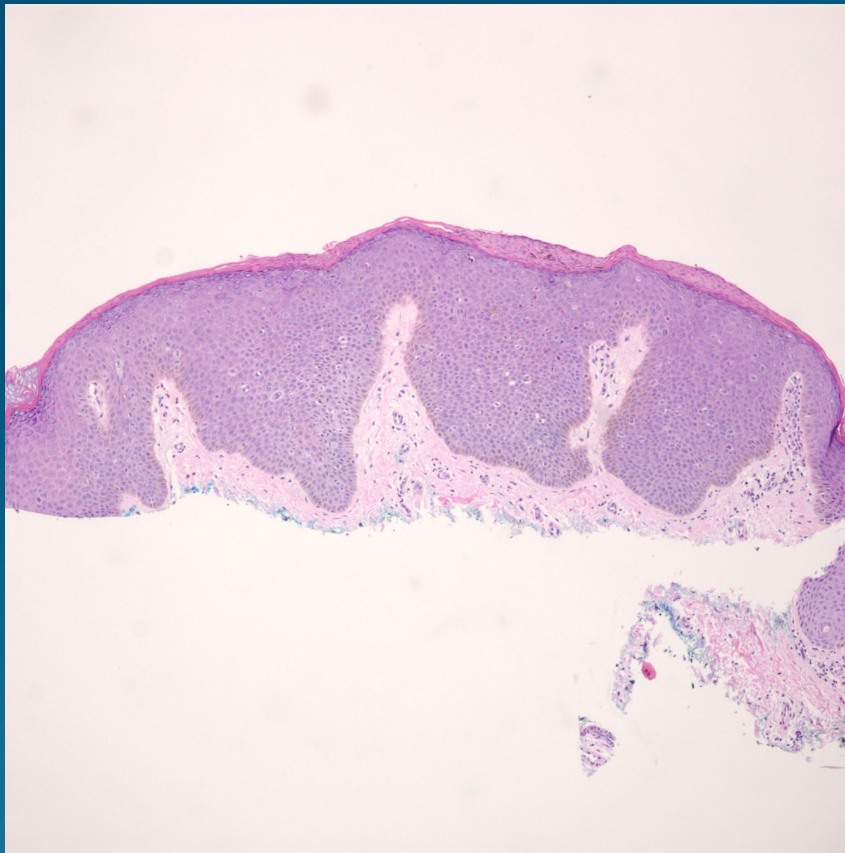


What is the best diagnosis?

- A. Condyloma
- B. Bowenoid papulosis
- C. Extramammary Paget's disease
- D. Basal cell carcinoma
- E. Hidracanthoma simplex

Bowenoid papulosis

Pearls



- Gently mammillated outline of epidermis with hyperchromatic crowded intraepithelial nuclei
- No koilocytes
- High grade nuclei through full epidermal thickness, scattered atypical mitotic figures